
Modified Meek Micrografting Technique for Wound Coverage in Extensive Burn Injuries

Abelardo Medina, MD, PhD, FACS, *†‡ Timothy Riegel, MD, FRCSC, ‡
Deborah Nystad, RN, ‡ Edward E. Tredget, MD, MSc, FRCSC*†‡

The modified Meek micrografting technique constitutes a rapid and efficient surgical approach for the skin coverage of extensive full-thickness burn injuries. A total of 10 burn patients (mean $68 \pm 9.2\%$ TBSA) admitted to our burn unit required one or more Meek micrografting procedures (mean 2.2 ± 0.5) to cover in average $43.4 \pm 11.6\%$ TBSA (range between 10 and 75% TBSA). This goal was achieved using a donor site area ranging between 2.5 and 18% TBSA. All patients developed local infection to *Pseudomona aeruginosa* (75%), *Stenotrophomona maltophilia* (25%), methicillin-resistant *Staphylococcus aureus* (12.5%), and *Acinetobacter baumannii* (12.5%). Thus, the average of Meek regrafting after graft-take failure was $13.1 \pm 6.4\%$ TBSA (median: 9%; range from 0 to 36%). The period to obtain stable definitive wound closure was in average of 67.2 ± 21 days post injury. The modified Meek micrografting provides a reliable and versatile method for the coverage of large burn wounds with limited autograft donor sites and is now routinely used in our institution. Its systematic use improves operating times and overall outcomes reducing the number of surgeries, increasing the percentage of graft take, and decreasing the length of stay. (J Burn Care Res 2016;37:305–313)

Early debridement and coverage with autologous skin grafts constitute the gold standard for the management of extensive full-thickness burn injuries.¹ Procedures for expanding skin grafts are regularly used to maximize the open wounds to be covered when existing donor sites of intact skin are limited. In this regard, even though it has been the most widely available method,² the meshing technique becomes difficult to carry out when donor sites are small.³ Thus, the resulting meshed autografts turn out to be hard to handle in high graft expansion rates.⁴ In addition, it is also a concern the presence of re-epithelialization delays or even failures and more susceptibility to infections with mesh expansions greater than 1:6.^{3,5}

From the *Wound Healing Research Group, Division of Plastic and Reconstructive Surgery, †Division of Critical Care Medicine, and ‡Firefighters' Burn Treatment Unit, Department of Surgery, University of Alberta, Edmonton, Canada.

Supplemental digital content is available for this article. Direct URL citations appear in the printed text and are provided in the HTML and PDF versions of this article on the journal's Web site. Address correspondence to Edward E. Tredget, MD, MSc, FRCSC, University of Alberta, 2D2.28 WMC, 8440-112 Street, Edmonton, Alberta T6G 2B7, Canada. Email: etredget@ualberta.ca.

Copyright © 2016 by the American Burn Association
1559-047X/2016

DOI: 10.1097/BCR.0000000000000244

A different approach to skin graft expansion was described by Meek in 1958.⁶ This method considers the basic concepts from the postage stamp technique⁷ incorporating a new mechanization that allows an efficient and quicker operating performance. Modifications introduced by Kreis et al⁸ to the original Meek technique have facilitated the manipulation of skin islands and the achievement of more stable results.

This report describes our experience with the modified Meek micrografting technique in extensive-burn patients.

METHODS

Data Collection

We performed a retrospective study of Meek micrografting procedures carried out in extensive-burn patients admitted to the Firefighters' Burn Treatment Unit at the University of Alberta. The approval for this study was obtained from the institutional ethic board. We reviewed the medical records of these patients to collect basic demographic data such as age, gender, type of injury, TBSA burns, donor site area, total burn surgeries, TBSA Meek grafted, Meek graft expansion rate, and length of stay (LOS). In addition, complications on the grafted areas with Meek procedures

such as local infection, percentage of graft take, superficial re-epithelialization, and cosmetic results with Meek skin stamps (skin pattern and pigmentation) are described. Data are expressed as mean \pm SEM.

Surgical Debridement

After fluid resuscitation period was completed and systemic stability achieved, patients were taken to the operating room to remove necrotic tissues. Thus, under general anesthesia and appropriate monitoring, patients were prepared and draped in the usual fashion. To reduce blood loss, tourniquets were routinely used in extremities. Debridements were performed in all full-thickness burn wounds using Braithwaite and Weck knives until healthy wound beds were reached. When indicated, fascial excisions were performed in some areas, such as back, anterior chest, and abdominal wall. Appropriate hemostasis was obtained with topical epinephrine and electrocauterization.

Modified Meek Skin Micrografting Procedure

Before the graft harvesting, all available donor sites for skin grafts were insufflated with warmed normal saline solution containing 1: 400,000 epinephrine. Using a Zimmer® air dermatome (Zimmer, Inc. Warsaw,

IN), 2-inch-wide and 10- to 12/1000-inch-thick skin grafts were harvested. The donor sites were dressed with xeroform™ (Kendall-Covidien, Mansfield, MA), burn gauzes, and burn nets. The split-thickness skin grafts were stretched out onto Zimmer® derma-carriers with the dermal side upward. Cork pieces (42×42mm) from the Meek micrografting system (Humeca, Enschede, The Netherlands) were soaked with normal saline for 5 min and then applied over the exposed dermal surface of split skin autografts (Figure 1A). This approach reduces the time utilized for graft preparation. Using No. 20 scalpel blades, the skin grafts were cut in between cork plates (Figure 1B). This step maximizes the use of skin grafts and their accurate allocation on the corks (Figure 1C). Two cork pieces containing skin grafts were placed in a cutting block that moves, along a crank, under a bridge during cutting (Figure 1D–F). The cutting machine contains 13 parallel round blades spaced 3mm apart from each other (Figure 2A). These air-driven blades incised every single 42- × 42-mm-sized unit of split skin autograft into 14 strips 3mm wide (Figure 2B, C). Subsequently, the carrier blocks containing the skin strips were rotated by 90° to be passed again through the cutting machine to produce 196 square microsized skin grafts (Figure 2D). At this time point, an aerosol adhesive was sprayed onto the epidermal surface

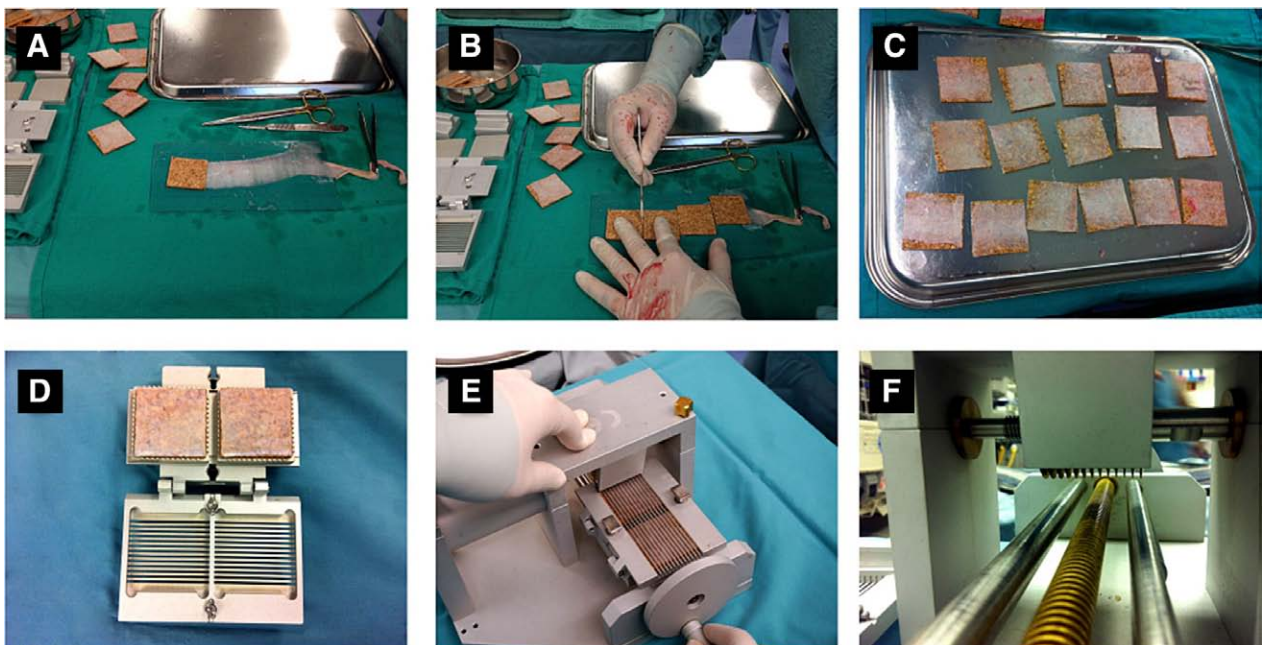


Figure 1. Modified Meek micrografting technique. The split-thickness skin grafts were stretched out onto plastic board with the dermal side upward and cork pieces (42×42 mm) were applied over the exposed dermal surface (A). The skin grafts were cut in between cork plates with No 20 scalpel blades (B). This step maximizes the use of skin grafts and their accurate allocation on the corks (C). Two cork pieces containing skin grafts were placed in a cutting block that moves, along a crank, under a bridge during cutting (D–F).




Figure 2. Modified Meek micrografting technique. The cutting machine contains 13 parallel round blades spaced 3 mm apart each other (A). These air-driven blades incised split skin autograft into 14 strips 3 mm wide (B and C). Then, the carrier blocks containing the skin strips were rotated by 90° to be passed again through the cutting machine to produce 196 square microsized skin grafts (D).

of the grafts and allowed to dry (see Figure, Supplemental Digital Content 1, available at <http://links.lww.com/BCR/A48>). This glued surface was pressed on polyamide gauze containing 14 × 14 square pleats matching the cut pattern in the split skin autografts

(Figure 3A). Each prefolded gauze carries an aluminum foil backing to facilitate later the manipulation and expansion of skin micrografts. After few minutes, cork plates could be gently removed from the skin micrografts, which continued only attached to the prefolded




Figure 3. Expansion of Meek skin micrografts (ratio 1:4). The glued surfaces of the 196 square microsized skin grafts were pressed on polyamide gauze containing 14 × 14 square pleats matching their cut pattern (A). In few minutes, cork plates could be gently removed from the skin micrografts, which continued only attached to the prefolded gauzes (B and E). Then, gauzes were pulled steadily and firmly from their notched edges until pleats were flattened in this direction (C and F). Subsequently, gauzes were held at the other edges and pulled until their pleats were also smooth in this direction (D and G).

gauzes (Figure 3B). Then, gauzes were pulled steadily and firmly from their notched edges until pleats were flattened in this direction. Subsequently, gauzes were held at the other edges and pulled until their pleats were also smooth in this direction (Figure 3C–G). At this time point, the margins of expanded gauze without skin micrografts were trimmed and the support of aluminum foil peeled off before the autograft islands stacked on the fabric were applied on debrided areas and secured in place with surgical staples (Figure 4A, B). The polyamide gauzes and inner layers of dressings were kept for 7 to 10 days while silver nitrate and/or sulfamylon/nystatin solutions were applied on a daily basis. At this time point, the skin stamps could be seen through the fabrics sticking to the surface of wound beds. As a result, polyamide gauzes were removed and daily dressings indicated until the epithelialization was complete (Figure 4C, D). Local assessment was regularly done to determine the need of additional debridements and skin grafts.

Statistical Analysis

Nonparametric tests were used to determine the statistical significance of the results. Specifically,

Mann–Whitney rank sum test was performed to evaluate independent sample medians using GraphPad InStat 3 (GraphPad Software Inc, La Jolla, CA) for Windows. Results are presented as mean \pm SEM, where a $P \leq .05$ was considered statistically significant.

RESULTS

During the study period, a total of 10 extensive-burn patients required modified Meek micrografting technique for skin coverage (Table 1). Within this group, nine patients were men and one patient was woman. Their mean age was 35.4 ± 5.2 years (range between 20 and 61). The cause of injury was flame burn in all cases. These patients presented extensive burns ($68 \pm 9.2\%$ TBSA; range between 35 and 90). The mean Baux score was 103.4 ± 10.8 (range between 68 and 136), and the mean abbreviated burn severity index was 10.3 ± 1.5 (range between 5 and 15).

As usual in these circumstances, these patients required fluid resuscitation with Parkland formula and intensive care management to prevent and/or treat multiple-organs failures. Compartment limb

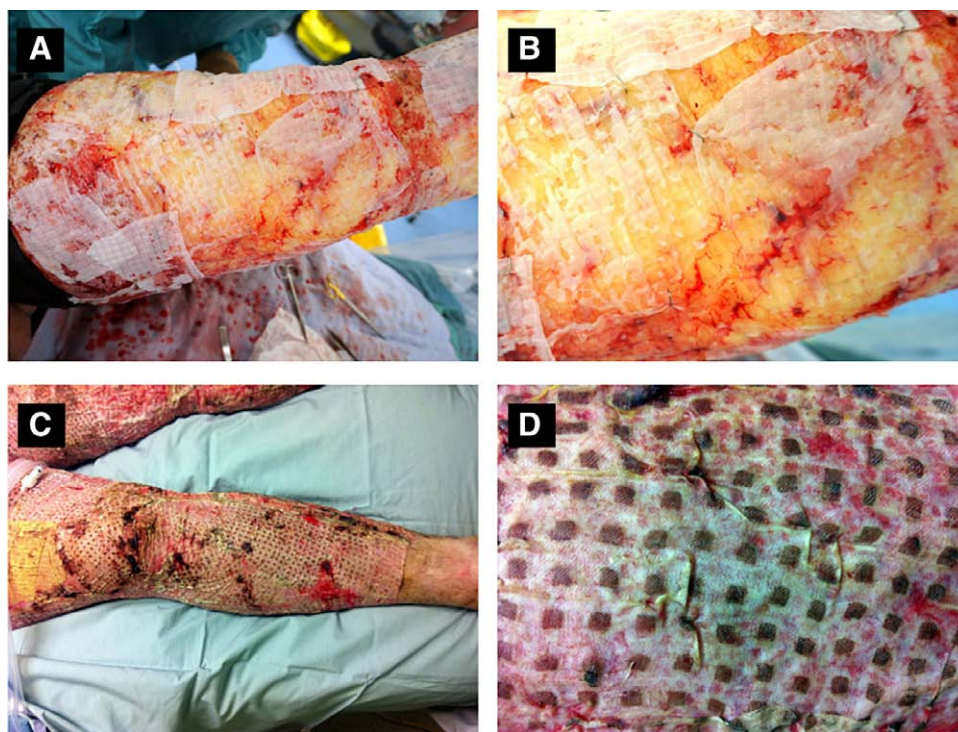


Figure 4. Application of modified Meek skin micrografts on a burn patient. The margins of expanded gauze without skin micrografts were trimmed and the support of aluminum foil peeled off before the autograft islands stacked on the fabric were applied on debrided areas and secured in place with surgical staples (A and B). After 7 to 10 days, the skin stamps could be seen through the fabrics sticking to the surface of wound beds. At this time point, polyamide gauzes were removed and daily dressings indicated until the epithelialization was complete (C and D).

Table 1. Demographics of burn patients requiring modified Meek skin micrografts

Patients	Age	TBSA (%)	Baux	ABSI	Donor (%)	Meek (%)	Regrafting (%)
HM	20	85	105	13	7.5	28	8
WM	45	90	135	15	8	64	8.5
HB*	61	75	136	14	10	75	7
BA	33	65	98	9	2.5	10	0
MW	36	75	111	10	18	63	18.5
WC	33	35	68	5	6	19	0
SM	34	43	77	7	5	16	0
DS	30	72	102	10	14	47	22
MS†	28	90	118	12	5	72	36
SM	34	50	84	8	15	40	25
Mean	35.4	68	103.4	10.3	9.1	43.4	13.1‡

ABSI, abbreviated burn severity index; *Baux*, Baux score; *TBSA*, total body surface area with burned injury; *donor*, percentage of TBSA as donor site for Meek procedure; *Meek*, percentage of TBSA with burned injury covered by modified Meek skin micrografts.

Regrafting (%): Percentage of TBSA covered with Meek skin micrografts that required regrafting due to graft take failure.

*Mortality, death before completing skin coverage.

†Female.

‡Mean excluding a patient that died before completing the skin coverage.

pressures were periodically measured during the resuscitation period, and decompressions were performed when needed.

Patients were taken to the operating room in multiple occasions for debridements associated with transitory or definitive burn wound coverage (mean 8 ± 3 surgeries). One or more procedures of Meek micrografting (mean 2.2 ± 0.5) were used to cover

excised deep burn wounds on scalp (10%), back (40%), upper limbs (80%), lower limbs (100%), buttocks (50%), chest (70%), and abdominal wall (50%).

In this study group, Meek micrografts covered in average $43.4 \pm 11.6\%$ TBSA (range between 10 and 75% TBSA). This goal was achieved using a mean of donor site of $9.1 \pm 2.3\%$ TBSA (range between 2.5 and 18%). The operating time using modified Meek

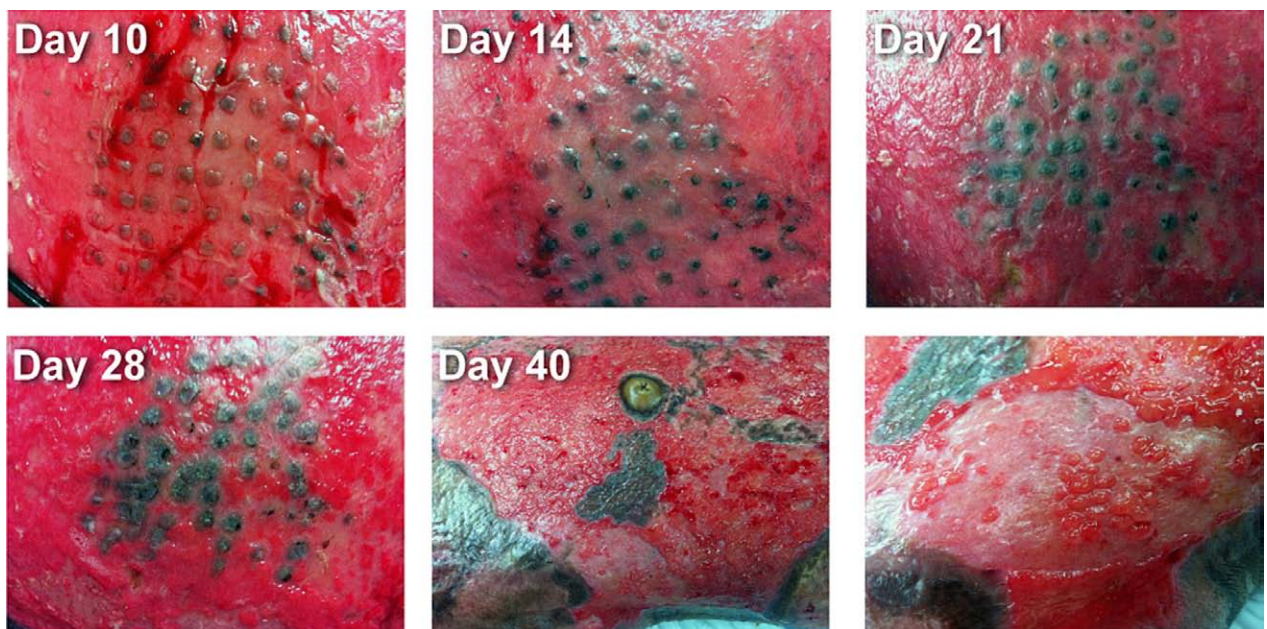


Figure 5. Modified Meek skin micrografts progression and epithelialization timing. After fabrics were removed (day 7 to 10), the skin stamps showed evidence of superficial progression until they reached contact each other and closed the open areas in approximately 4 to 5 weeks after surgery (upper and left lower panels). In general, modified Meek skin micrografts showed more stable coverage compared to meshed STSG applied at the same time (middle and right lower panels).

procedure was significantly shorter compared with that with mesh graft technique for similar debrided burn areas (6.57 ± 1 hr vs 9.69 ± 2.1 hr; P value = .05). In our experience, after fabrics were removed, the skin stamps showed evidence of superficial progression until they contacted each other and closed the open areas in approximately 4 to 5 weeks after surgery (Figure 5).

All patients developed local infection following Meek micrografting procedures (Figure 7 and Table 2). The identified microorganisms were *Pseudomonas aeruginosa* (75%), *Stenotrophomonas maltophilia* (25%), methicillin-resistant *Staphylococcus aureus* (12.5%), and *Acinetobacter baumannii* (12.5%). In this regard, excluding a patient who died before completing the skin coverage (Table 1), the average of Meek regrafting after graft-take failure was $13.1 \pm 6.4\%$ TBSA (median: 9%; range from 0 to 36%). These results represent a success rate of 74.4% (range from 37.5 to 100%) for skin grafting with modified Meek technique in our study group.

One patient died during his stay in hospital due to complications of sepsis and multiple-organ dysfunction syndrome. This patient had significant past medical history of coronary disease that required angioplasty and coronary stent, prostate cancer treated with brachytherapy, depression, hypertension, and dyslipidemia. Another patient stayed in hospital for 557 days due to pancreatic ascitis as a result of pancreatic duct leak leading to severe nutritional deconditioning, multiple intra-abdominal fluid collections, and frozen abdomen. Excluding these two patients, the LOS was in average of 86 days (SEM \pm 30), and the period to obtain stable definitive wound closure was in average of 67.2 days post injury (SEM \pm 21).

DISCUSSION

The meshing technique is the most common tool for expanding skin autografts in extensive burn injuries. However, this method is far from ideal since it provides extremely fragile meshed skin grafts when graft expansion rates greater than 1:4 are used. The difficulty to

handle widely expanded meshed skin grafts and perform their appropriate stretching during surgeries constitutes the major reasons why skin graft meshers may not be able to reach the expected graft expansion in critical situations of limited donor sites.^{4,9,10} In addition, large graft expansions also leave significant areas of exposed surgical wounds in the interstices that may cause delays or even failures in re-epithelialization and higher incidences of infection.^{3-5,11} Thus, micrografting techniques constitute surgical options to improve the graft expansion of available areas for skin harvesting. In this regard, however, traditional micrografting methods may result in uncontrollable orientation and unpredictable distribution of the skin graft islands increasing the operating times and reducing the rates of success.⁴

The modified Meek micrografting technique provides a systematic and careful handling of skin graft islands, which are distributed in a regular pattern and with the right orientation. As a result, this technique allows a rapid and reliable surgical approach to cover considerably large areas of debrided burns with minimal and sometimes scattered donor sites (Figures 1, 4, and 6; Table 1). Thus, the modified Meek technique divides 42- \times 42-mm pieces of split skin autografts into 196 skin graft islands measuring 3 \times 3 mm each (Figure 2). The prefolded polyamide gauzes with aluminum foil backing generate graft expansion ratios of 1:3, 1:4, 1:6, and 1:9 (Figure 3; see Figure, Supplemental Digital Content 1, available at <http://links.lww.com/BCR/A48>). Because the graft expansion relies on the prefolded fabrics rather than on skin grafts, the modified Meek technique exhibits a more accurate expansion ratio compared with that from mesh graft technique.¹² In addition, due to the presence of fabrics and the use of staples to tack the graft islands down to the wound bed, the Meek procedure reduces the risk of graft shifting.

In our experience, this technique along with the long-term implemented systemic and local managements (see "Methods") allowed us to perform Meek grafts in up to 47% TBSA in a single operating session (Table 1). Furthermore, because it work better than meshing technique with tiny graft remnants and is easy to handle, Meek grafting is a safe option for grafting "patchy" open wounds (Figure 6). When combined with traditional meshed split-thickness skin grafts, the use of Meek procedure for "less functional areas" allowed us to have enough donor sites to cover more sensitive areas with better quality skin grafts (ie, 1:1 expansion on hands).¹³

In our study group, the skin graft expansion reached with this technique was 1 to 5.1. In areas with favorable course, the re-epithelialization time was between 4 and 5 weeks after Meek grafting (Figures 5 and 6).

Table 2. Distribution of local infections in areas covered by modified Meek skin micrografts

	%
Ps. aeruginosa	75
S. maltophilia	25
MRSA	12.5
A. baumannii	12.5

A. *Baumannii*, *Acinetobacter baumannii*; MRSA, methicillin-resistant *Staphylococcus aureus*; Ps. *Aeruginosa*, *Pseudomonas aeruginosa*; S. *Maltophilia*, *Stenotrophomonas maltophilia*.

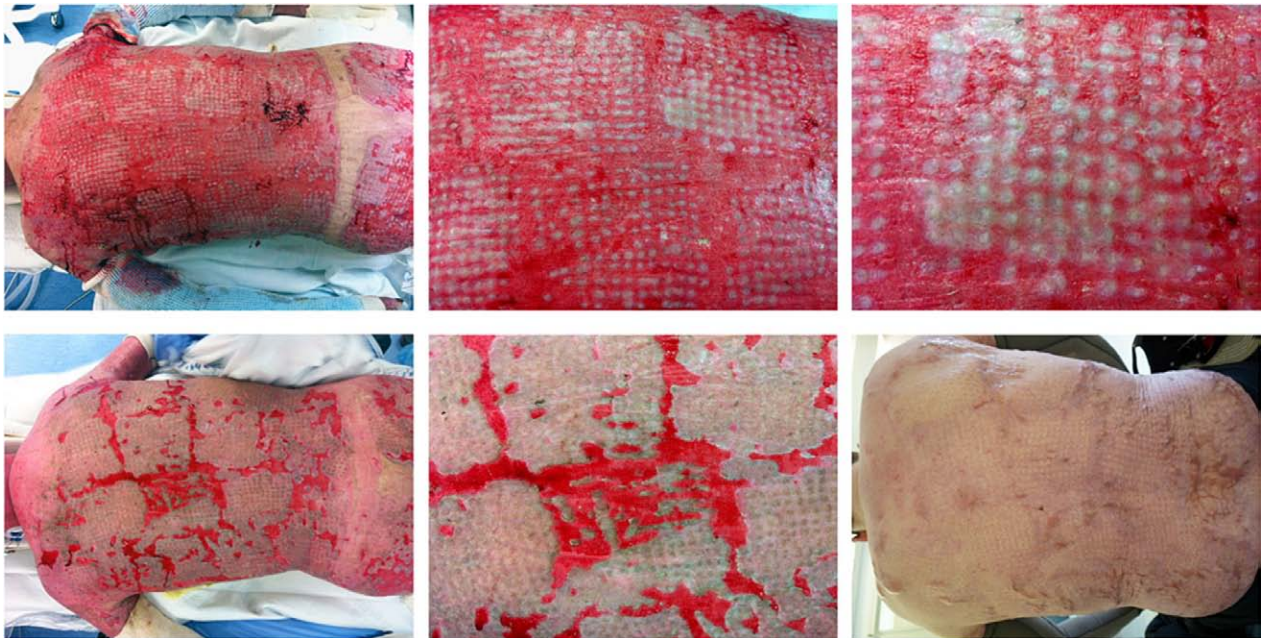


Figure 6. Application of modified Meek skin micrografts on the back of a patient with 75% TBSA flame burn. After surgical debridement, Meek skin micrografts were applied to the back resulting in an appropriate graft take (upper panels). However, several open wounds were left behind among fabrics carrying small postage stamp skin grafts (left and middle lower panels). A second surgery was required to cover these patchy areas. Long-term follow-up 1 year after initial injury (right lower panel).

At that point in time, Meek grafts appeared more stable than neighboring meshed split-thickness skin grafts in a clinical case of extensive-burn injury and severe nutritional deconditioning (Figure 5).

We did not use cadaveric skin as biological dressings to cover the Meek micrografts because these allogeneic materials have a limited benefit protecting the Meek skin islands against infection.⁸ Instead, the strong attachment of overlay allografts (especially fresh allografts) to the wound bed may delay the re-epithelialization progression from the edges of the Meek autograft islands. In addition, the overlay allografts have the theoretical risk of triggering a donor-specific human leukocyte antigen sensitization.

We did not use cultured epithelial autograft (CEA) to accelerate the burn wound closure after Meek procedures.¹¹ This approach introduces a number of concerns such as the use of no human growth supplements to culture epithelial cells and their subsequent manipulation (ie, cell harvesting and subcultures, cell transportation, etc.). Currently, a study with small sample size without case-control comparison has been published.¹¹ In that article, it is difficult to assess the benefit of CEA especially because five of seven cases presented with partial-thickness burns, which have the potential to heal by their own. Therefore, more studies with larger number of cases are required to establish the real role of CEA in conjunction with modified Meek techniques.

Interestingly, the Meek graft islands seem to be more resistant to invasion by microorganisms. Thus, even though our 10 patients experienced local infections (Table 2), the appropriate topical management and systemic antibiotic therapies allowed the Meek skin grafts to survive and resume their re-epithelialization process when the local condition improved (Figure 7). Unlike meshed skin grafts, the lack of continuity among Meek graft islands may limit the infection problems to small areas rather than stimulate the bacterial growth and progression along wound beds.⁴ It has also been suggested that the shorter distance between Meek graft islands compared with a Tanner meshed graft may also contribute to this resistance to infections.⁵ This may be an especially advantage feature in cases of extensive burn injuries with delayed transfer and already established bacterial colonization and/or infection.

It seems that Meek grafting technique has better graft-take rate compared with other grafting procedures, even in challenging areas and in low-quality wound beds.⁴ Thus, we applied Meek grafts on decorticated leg bones in two of our patients, resulting in appropriate graft take and stable long-term wound coverage (Figure 8). In addition, we applied Meek grafts on open wounds of three burn patients that were previously covered with Integra[®] dermal matrix (see Figure, Supplemental Digital Content 2, available at <http://links.lww.com/BCR/A49>).¹⁴ In those cases, we obtained more than 75% graft-take rate. The role of this association between

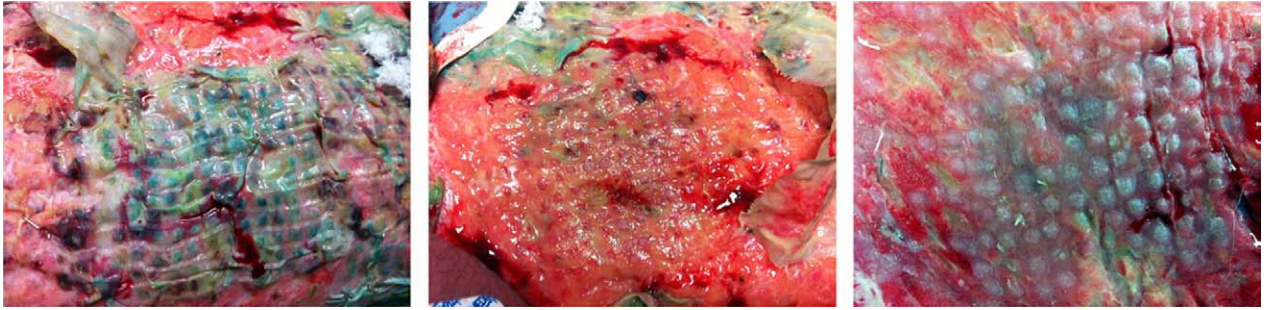


Figure 7. Modified Meek skin micrografts and local infection. Modified Meek skin micrografts with expansion ratio of 1:6 and local infection to multidrug-resistant *Pseudomonas aeruginosa*. Local condition during daily assessment (left panel) and after removal of polyamide gauze (middle panel). In general, the appropriate topical management and systemic antibiotic therapies allowed the Meek skin grafts to survive and resume their re-epithelialization process (right panel).

Integra® dermal matrix and Meek technique requires further investigations by experienced burn surgeons within a highly specialized clinical settings.

In regard to functional and cosmetic results, because the number of cases in our practice is still limited, it is difficult to reach any definitive conclusion or make any valid comparison with meshed grafting techniques. However, we found that the appearance of the skin pattern, local pigmentation, and tissue pliability will depend, at least in part, on the type of skin, expansion rate, and graft stretching, and location of donor sites and grafted areas. In our experience, darker skins generated stronger pigmentation on original skin graft islands compared with

the original meshed skin grafts. Both techniques exhibited similar pigmentation on the re-epithelialized interstices (Figure 9). We found that the wider expansion on Meek grafts, the more limited pliability of the resulting skin coverage (see Figure, Supplemental Digital Content 3, available at <http://links.lww.com/BCR/A50>). In this regard, the 1:4 and 1:6 expansions on Meek grafts were fairly similar to the 1:2 and 1:3 expansions on meshed grafts, respectively. These clinical outcomes may significantly change from one patient to another and according to different contributing factors such as genetic background, depth of wounds, use of Integra®, timing for autografting, needs of regrafting, and presence of

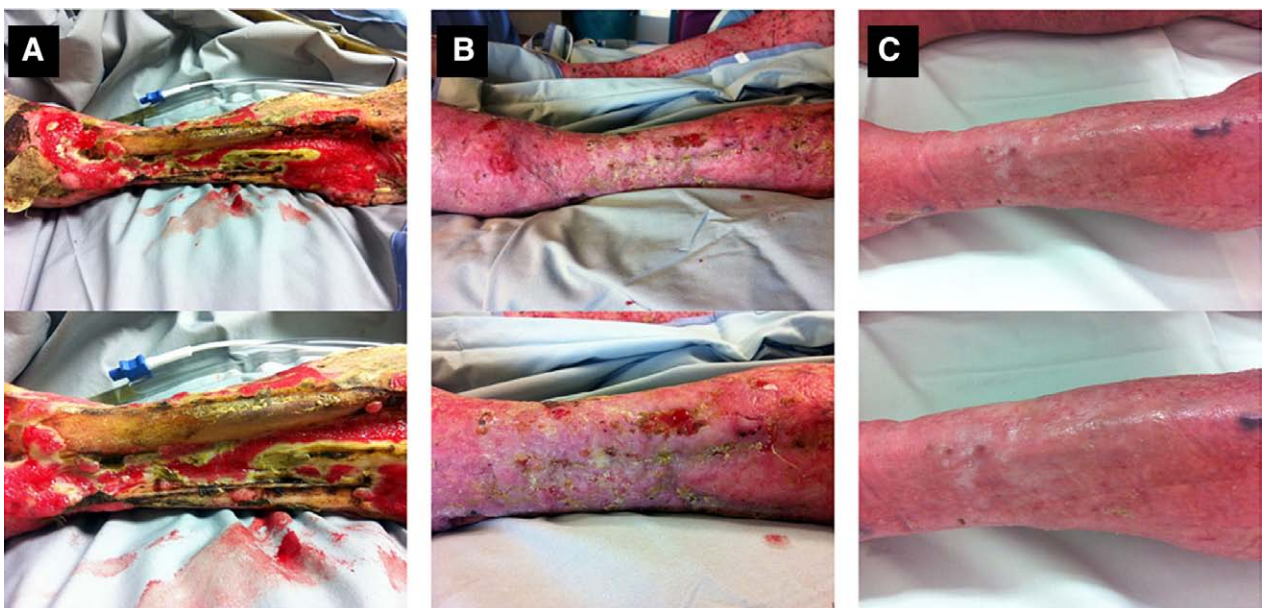


Figure 8. Modified Meek skin micrografts application on exposed bone. Meek grafting technique has good graft take rate in challenging areas and in low quality wound beds. Thus, Meek grafts have appropriate graft take and stable long-term wound coverage on exposed bones. A: A Preoperative view of an extensive burn patient (90% TBSA) with exposed tibia. Patients requested bone decortication and modified Meek skin micrografts. B: A view 1 month after surgery and C displays the local condition 1 year after surgery. STSG, split-thickness skin graft.

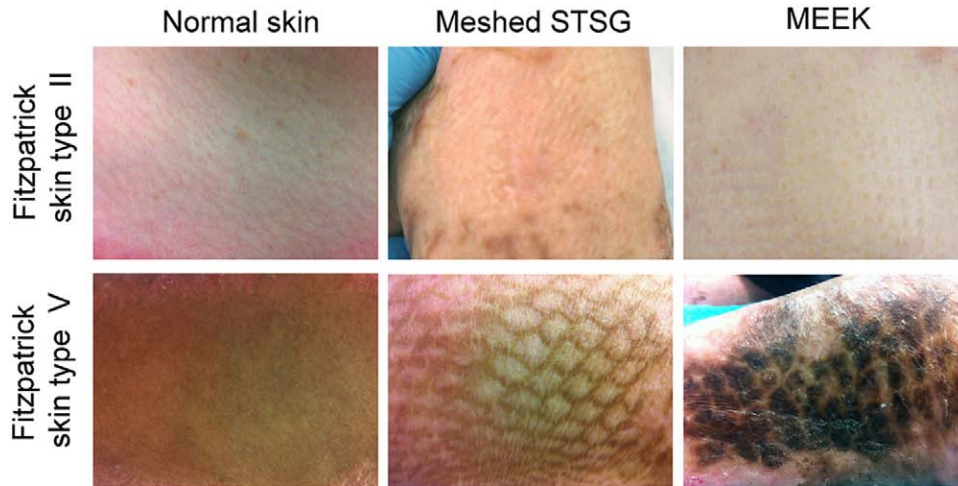


Figure 9. Skin pattern comparison between meshed STSG and Meek grafts. Upper panels show the normal skin (left), 1:2 expansion ratio of meshed STSG (middle), and 1:6 expansion ratio of Meek skin micrograft (right) in a burn patient with Fitzpatrick skin type II. Lower panels show the normal skin (left), 1:3 expansion ratio of meshed STSG (middle), and 1:4 expansion ratio (right) in a burn patient with Fitzpatrick skin type V. STSG, split-thickness skin graft.

local infection or maceration, among others. Indeed, smaller expansions on meshed skin grafts (1:2 ratio or less) may produce better cosmetic outcomes and higher skin pliability; however, they have limited potential in terms of open wound coverage.

Excluding the necessary expenses for any extensive burn surgery (ie, fluids and drugs, materials for debridement procedures and dressings, etc.), the cost in specific materials (excluding the cutting machine) to perform a Meek micrografting technique in our institution is approximately US\$ 60 per 1% TBSA. Other authors' reports suggest that these expenses may be offset by savings from reducing the operating times, increasing the percentage of graft take, and decreasing the LOS.¹² Accordingly, our preliminary comparative analysis has shown that the systematic use of modified Meek technique for the coverage of extensive burn injuries improved the operating times. However, a further matched-case study with large number of patients is required to determine the definitive impact of this technique on the overall outcomes.

CONCLUSION

The modified Meek micrografting technique provides a reliable and versatile approach for coverage of large burn wounds and is now our method of choice for extensive-burn patients with limited autograft donor sites. The positive experiences from our group and others with the modified Meek grafting raise the question on the current role and indications for tissue-engineered skin substitutes in burn injuries especially in developing countries.

REFERENCES

1. Tompkins RG, Burke JF, Schoenfeld DA, et al. Prompt eschar excision: a treatment system contributing to reduced burn mortality. A statistical evaluation of burn care at the Massachusetts General Hospital (1974-1984). *Ann Surg* 1986;204:272-81.
2. Tanner JC Jr, Vandeput J, Olley JF. The mesh skin graft. *Plast Reconstr Surg* 1964;34:287-92.
3. Kreis RW, Vloemans AF. Fixation of skin transplants in burns with SurfaSoft and staples. An analysis of the results. *Scand J Plast Reconstr Surg Hand Surg* 1987;21:249-51.
4. Kreis RW, Mackie DP, Hermans RR, Vloemans AR. Expansion techniques for skin grafts: comparison between mesh and Meek island (sandwich-) grafts. *Burns* 1994;20(suppl 1):S39-42.
5. Hsieh CS, Schuong JY, Huang WS, Huang TT. Five years' experience of the modified Meek technique in the management of extensive burns. *Burns* 2008;34:350-4.
6. Meek CP. Successful microdermagrafting using the Meek-Wall microdermatome. *Am J Surg* 1958;96:557-8.
7. Chih-chun Y, Tsi-siang S, Wei-shia X. A Chinese concept of treatment of extensive third-degree burns. *Plast Reconstr Surg* 1982;70:238-54.
8. Kreis RW, Mackie DP, Vloemans AW, Hermans RP, Hoekstra MJ. Widely expanded postage stamp skin grafts using a modified Meek technique in combination with an allograft overlay. *Burns* 1993;19:142-5.
9. Peeters R, Hubens A. The mesh skin graft—true expansion rate. *Burns Incl Therm Inj* 1988;14:239-40.
10. Kamolz LP, Schintler M, Parvizi D, Selig H, Lumenta DB. The real expansion rate of meshers and micrografts: things we should keep in mind. *Ann Burns Fire Disasters* 2013;26:26-9.
11. Menon S, Li Z, Harvey JG, Holland AJ. The use of the Meek technique in conjunction with cultured epithelial autograft in the management of major paediatric burns. *Burns* 2013;39:674-9.
12. Raff T, Hartmann B, Wagner H, Germann G. Experience with the modified Meek technique. *Acta Chir Plast* 1996;38:142-6.
13. Lumenta DB, Kamolz LP, Frey M. Adult burn patients with more than 60% TBSA involved-Meek and other techniques to overcome restricted skin harvest availability—the Viennese Concept. *J Burn Care Res* 2009;30:231-42.
14. Papp A, Härmä M. A collagen based dermal substitute and the modified Meek technique in extensive burns. Report of three cases. *Burns* 2003;29:167-71.